



## Treatment of methaemoglobinemia in dogs following ingestion of baits containing PAPP

### Introduction

A new toxin for wild dog and fox management has been released in Australia. Known as DOGABAIT and FOXECUTE®, the new baits contain the chemical para-aminopropiophenone (or 'PAPP'), which induces **methaemoglobinemia** following ingestion.

Veterinarians may be presented with cases of off-target poisoning of domestic pets, and so need to be aware of the mode of action of the toxin and its antidote, in order to attempt management of these cases.

Foxecute bait dosage is 400mg and Dogabait dosage is 1000mg of PAPP. Knowing which of these baits has been accidentally ingested may help with clinical decision making and determination of appropriate antidote dosage.

### General considerations - methaemoglobinemia

Methaemoglobin occurs as the result of oxidative damage to haemoglobin, which can be induced in cats and dogs by several chemicals, e.g. naphthalene (mothballs), onions and garlic (typically in dogs after a BBQ) and paracetamol (especially in cats).<sup>1,2</sup> Local anaesthetics, such as benzocaine, can also cause significant methaemoglobinemia if not carefully administered.<sup>2,3</sup>

The chemical PAPP in the new baits bio-transforms in the liver of eutherian carnivores to a metabolite that rapidly oxidises haemoglobin to methaemoglobin.

### Clinical signs

Clinical signs of methaemoglobinemia include lethargy, cyanosis, ataxia, unresponsiveness, unconsciousness and death.

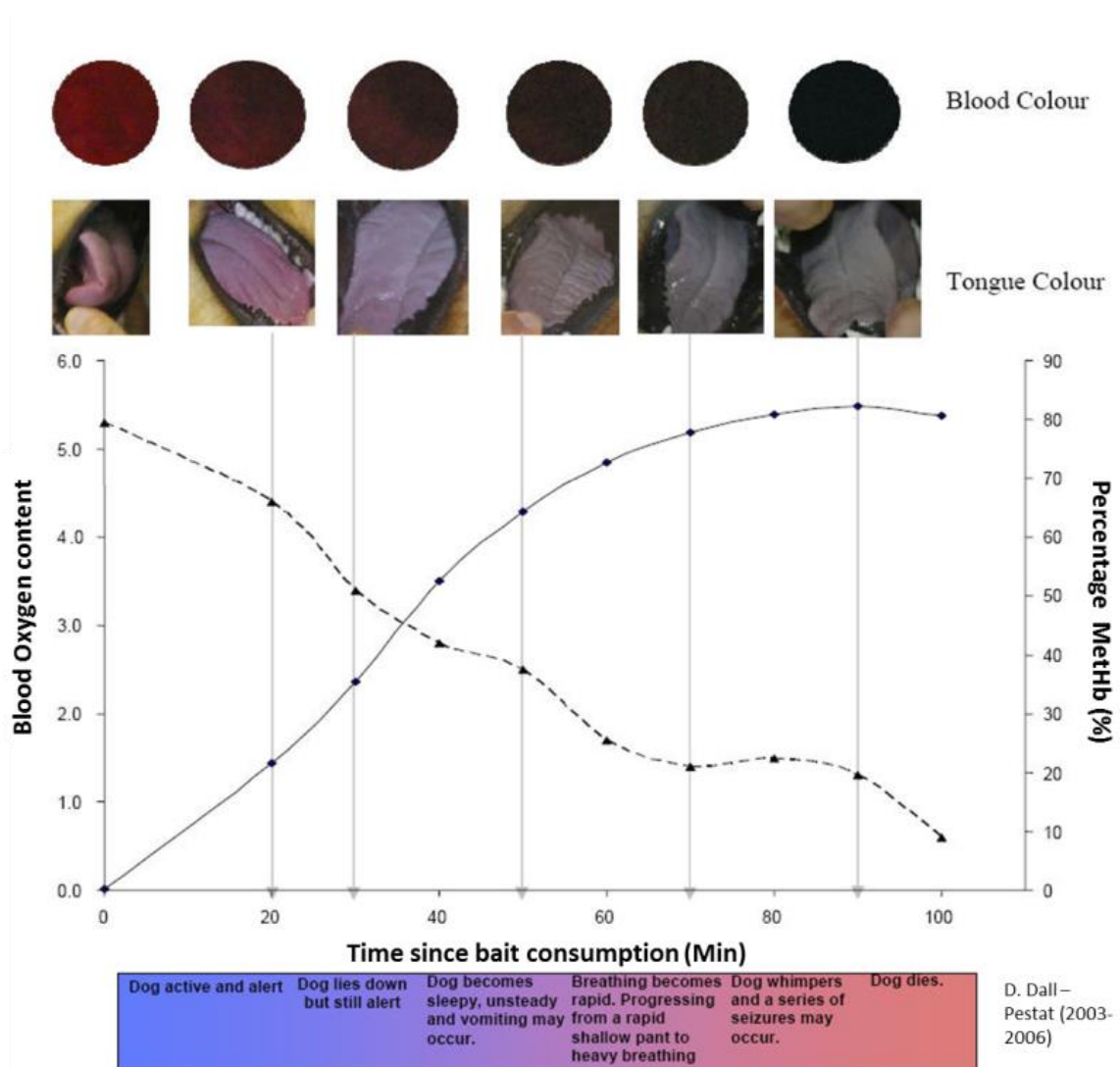
Blood containing high concentrations of methaemoglobin is chocolate brown in colour (Figure 1) and cannot transport oxygen efficiently.

Minor amounts of methaemoglobin in the blood may be reduced back to active haemoglobin by innate enzyme systems. However, significant haemoglobin oxidation can disable oxygen transport to the point of hypoxia, anoxia, and death.

**PAPP baits contain bright yellow marker beads which will show up in the vomitus from affected animals. This will help to distinguish from poisoning by other intoxicants.**

NB. Some (though not all) 1080 baits contain red marker beads.

Figure 1. Diagrammatic representation of the stages of methaemoglobinaemia due to PAPP ingestion



**Treatment of methaemoglobinemia: METHYLENE BLUE (Veterinary–Systemic)**

Methylene blue injection is available for veterinary use in Australia under an APVMA permit PER13488.

**ORDERING:** Phebra – 1800 720 020; [orders@phebra.com](mailto:orders@phebra.com); [www.phebra.com](http://www.phebra.com)

Methylene Blue Injection is a registered TGA-approved medicine and so veterinary prescribing rights enable a registered veterinarian to access this for single animal use via a script to a pharmacy without the requirement for a permit. However, if the veterinarian wishes to have the product on hand for future use (or in case of emergency) rather than for an animal currently in their care at the time of supply, then the drug is supplied under the APVMA permit.

**Note Well:** ‘New Methylene Blue’ is a distinct product and not approved as an anti-methaemoglobinaemic

## TREATMENT OF POISONING IN DOGS:

Acute methaemoglobinaemia induced by ingestion of baits containing PAPP in dogs may warrant the administration of intravenous (IV) methylene blue; however, such use should take into consideration the potential adverse effects of methylene blue administration.

**There is a limited therapeutic window above which methylene blue may cause Heinz body formation** in cat and dog erythrocytes; in addition, another histopathological change, described as “blistering,” may appear in dog erythrocytes. The occurrence and severity of resulting erythrolysis and anaemia is dose-dependent; however, debilitated animals appear to be more susceptible. **This limits the dose that can be used in a single administration, and also the cumulative total dose that can be used therapeutically.**

When methylene blue is administered, careful dosing, concurrent fluid therapy, and post-treatment monitoring for 3 – 4 days are recommended.<sup>4-10</sup>

## TREATMENT RECOMMENDATIONS:

**(A) Early PAPP toxicosis: less than 50% MetHb. Clinical signs: lethargy, ataxia, mild-moderate cyanosis.**

NB. Centrifugation of blood in a microhaematocrit tube is useful to assess percentage of affected RBCs – these will appear brownish in colour and layer out separately to normal RBCs. Some blood gas machines can measure methaemoglobin percentage using oximetry.

1. **Induce vomiting** by administration of emetic IV (e.g. apomorphine 0.04 mg/kg IV or conjunctivally) (or 2-3 washing soda crystals or syrup of ipecac *per os*). Consider gastric lavage if vomiting is unsuccessful.
2. **Fluids:** place an IV catheter in the cephalic (or other) vein and connect to an infusion pump delivering Hartmann’s or similar crystalloid at a rate of 5 mL/kg/hour for the first 4 hours
3. **Administer methylene blue injection at a dose rate of 5mg/kg IV titrated over 5 minutes diluted in 5-10 times the volume of 5% dextrose in water (D5W);** use the side port of the line delivering crystalloids into the patient. Do not dilute methylene blue solution in 0.9% saline as this may precipitate the methylene blue. Methylene blue injection is also not compatible with either Hartman’s or 2.5% dextrose and 0.45% NaCl solution.
4. **Monitor** animal for improving clinical signs of oxygenation, e.g. less cyanosis. N.B. pulse oximetry is not able to differentiate methaemoglobin from oxyhaemoglobin and therefore is of no use for evaluating the response to therapy. Serial examination of mucous membrane colour and the appearance of microhaematocrit tubes after centrifugation are helpful.
5. **If clinical signs deteriorate** administer additional methylene blue injection diluted into D5W (0.2mg/mL) at a dose of 5mg/kg over 60min using an infusion pump or syringe driver.
6. Note: the maximum total dose of methylene blue must not exceed 10mg/kg.

(B) **Late PAPP toxicosis:** 50-70% MetHb. Clinical signs: sternal or lateral recumbency, unresponsive, elevated heart rate, severe cyanosis

1. **Do NOT try to induce vomiting** – TOO RISKY in relation to potential aspiration (consider induction of vomiting *after* the dog shows a favourable response to the antidote)
2. **Administer methylene blue injection** at a dose rate of 5mg/kg IV titrated over 5 minutes diluted in 5-10 times the volume of 5% dextrose in water (D5W)
3. **Monitor** for clinical signs of improved oxygenation (especially mucous membrane colour, microhaematocrit assessment).
4. **Consider gastric lavage** if patient remains unresponsive, followed by instillation of activated charcoal slurry at standard doses. Or if patient is sufficiently improved, induce vomiting as for (A) above.
5. **Monitor** animal for clinical signs of improvement
6. **If clinical signs deteriorate** administer methylene blue injection diluted into 5% glucose solution (0.2mg/ml) IV using a syringe driver or an infusion pump over 60min.
7. Note: the maximum total dose of methylene blue must not exceed 10mg/kg.

#### Adjunctive supportive therapy

- Activated charcoal 2-8 mg/kg *per os* (repeat as necessary)
- Oxygen therapy; ventilation is generally not necessary
- Maintenance fluid therapy using a crystalloid such as Hartmann's solution or Normosol R - 5 mL/kg/hour for the first 4 hours (in case of incipient dehydration; and to ensure good renal perfusion and urine production), then 2-3 mL/kg/hr using an infusion pump
- Reduce stress by keeping patient in a quiet environment with suitable ambient temperature; if the rectal temperature is less than 38°C, provide supplementary heat using radiant heat, warmed bags of fluid as hot water bottles or force air warming
- If dogs only partially respond to this treatment, exchange transfusion can be lifesaving but adds an extra layer of complexity to the treatment regimen. This involves removing blood from the patient's jugular vein – perhaps 10-20 mL/kg using a human blood collection pack, and replacing it with a similar volume of fresh whole blood, stored blood or half the volume of packed cells. In order for this to be effective, the dog should have either vomited or have had gastric lavage, and methylene blue at full doses should already have been administered (otherwise the 'fresh' transfused cells will be subjected to oxidative damage themselves).

#### Patient monitoring

The following may be especially important in patient monitoring (other tests may be warranted in some patients, depending on condition):

- Complete blood count and haematocrit (packed cell volume) and reticulocyte count. Monitoring red cells for oxidative changes and/or haemolytic anaemia is important in cats and dogs. In cats and dogs, anaemia may take 3 to 4 days to develop after ingestion.
- Once clinical signs appear, about 40 to 50% of haemoglobin will already have been oxidized to methaemoglobin; in excess of 80% is generally lethal.<sup>11,12</sup>
- Cyanosis: mucous membrane colour may be used as an indicator of toxicosis severity and recovery.

## TREATMENT OF OVERDOSE WITH METHYLENE BLUE:

Treatment may include the following:

- Monitoring for and treatment of haemolytic anaemia
- Supportive therapy e.g. diuresis

## CONTRAINDICATIONS:

Do not exceed 10mg/kg of methylene blue injection solution over 12 hours

Do not administer subcutaneously or intramuscularly as necrosis will occur

Do not administer to:

- Dogs with severe renal impairment
- Dogs with a known hypersensitivity to methylene blue
- Dogs with a glucose-6-phosphate dehydrogenase deficiency

The presence of severe anaemia should be considered as a potential contraindication (see below re: hypersensitivity to methylene blue)

## Additional Medical Considerations/Contraindications:

### *Hypersensitivity to methylene blue*

Cats and dogs - Renal failure or risk factors for acute kidney injury, including acidosis, dehydration, hypercalcemia and chronic hypoxia (because dose-dependent erythrocyte oxidation occurs with toxic doses of methylene blue in cats and dogs). Heinz body formation or other oxidative changes may lead to erythrocyte destruction, increasing the risk of haemoglobinuric nephrosis.<sup>4,6</sup>

Risk-benefit should be considered when the following medical problems exist:

Cats and dogs: Anaemia, severe, or haemolytic anaemia. Because of erythrocyte oxidation caused by methylene blue, the presence of pre-existing severe anaemia should be considered in the decision to treat and the dosage administered.<sup>4,6</sup>

## DOSAGE FORMS

Parenteral

METHYLENE BLUE INJECTION (see product label and leaflet)

Packaging and storage: Store below 25°C, do not freeze. Protect from light. The shelf life is 3 years (36 months) when stored as recommended.

### Dosing and Dosage Forms Note:

Methylene blue injection is formulated 10mg/mL in non-isotonic sterile water for injection (5ml/vial packaged in 7ml glass vials) and should be administered slowly e.g. 1ml/minute IV or via an continuous dose infusion.

**Do not dilute methylene blue solution in 0.9% saline as this may precipitate the methylene blue. Do not dilute in Hartman's or 2.5% dextrose and 0.45% NaCl solution.**

If dilution is required dilute in sterile 5% glucose solution

## ADVERSE EVENTS

To report an adverse event associated with the use of this product, or for questions concerning the product, contact: Poonam Kamboj: Pharmacovigilance & Medical Information Manager

P: +61 (0)2 9420 9199 (ext. 926) F: +61 (0)2 9091 2342

E: [poonam.k@phebra.com](mailto:poonam.k@phebra.com) E: [pharmacovigilance@phebra.com](mailto:pharmacovigilance@phebra.com) E: [medical@phebra.com](mailto:medical@phebra.com)

**NOTE:** This fact sheet has been developed with currently available information, however it is likely that treatment recommendations will be refined as new information becomes available from veterinarians in the field. It is hoped that soon oral or intraperitoneal methylene blue may become available so farmers will be able to implement therapy in the field, and then transport their dog to a nearby town for veterinary attention.

PAPP is a new poison and the antidote has been subject to only limited trials, so we would value feedback from veterinarians on use of the antidote and any supportive treatments, including outcomes and any adverse reactions. This will be critical for developing best practice guidelines for the treatment of pet and working dogs going forward.

Veterinarians who wish to provide feedback from their experiences treating cases of PAPP intoxication are encouraged to email the contact below so that protocols can be adapted where necessary.

Please contact Dr Melanie Latter, AVA Veterinary Affairs Manager: [melanie.latter@ava.com.au](mailto:melanie.latter@ava.com.au)

**Acknowledgements:** the assistance of Animal Control Technologies Pty Ltd (ACTA) is appreciated in the development of this fact sheet

## References

1. Rumbelha WK, Lin Y, Oehme FW. Comparison of N-acetylcysteine and methylene blue, alone or in combination, for treatment of acetaminophen toxicosis in cats. *Am J Vet Res* 1995; 56(11): 1529-33.
2. Beasley V. Methemoglobin producers. In: Beasley V, editor. *Veterinary Toxicology*. Ithaca, New York: International Veterinary Information Service. Available at [www.ivis.org/advances/Beasley/toc.asp](http://www.ivis.org/advances/Beasley/toc.asp). Accessed on January 29, 2008.
3. Wilkie DA, Kirby R. Methemoglobinemia associated with dermal application of benzocaine cream in a cat. *J Am Vet Med Assoc* 1988 Jan 1; 192(1): 84-6.
4. Fingerroth JM, Smeak DD. Intravenous methylene blue infusion for intraoperative identification of parathyroid gland tumors in dogs. Part III: clinical trials and results in three dogs. *J Am Anim Hosp Assoc* 1988 Mar/Apr; 24: 175-82.
5. Fingerroth JM, Smeak DD, Jacobs RM. Intravenous methylene blue infusion for intraoperative identification of parathyroid gland and pancreatic islet-cell tumors in dogs. Part I. Experimental determination of dose-related staining efficacy and toxicity. *J Am Anim Hosp Assoc* 1988 Mar/Apr; 24: 165-73.
6. Fingerroth JM, Smeak DD. Intravenous methylene blue infusion for intraoperative identification of pancreatic islet-cell tumors in dogs. Part II: clinical trials and results in four dogs. *J Am Anim Hosp Assoc* 1988 Mar/Apr; 24: 175-82.
7. Harvey JW, King RR, Berry CR, et al. Methaemoglobin reductase deficiency in dogs. *Comp Hematol Int* 1991; 1: 55-9.
8. Smeak DD, Fingerroth JM, Bilbrey SA. Intravenous methylene blue as a specific stain for primary and metastatic insulinoma in a dog. *J Am Anim Hosp Assoc* 1988; 24(5): 478-80.
9. Osuna DJ, Armstrong PJ, Duncan DE, et al. Acute renal failure after methylene blue infusion in a dog. *J Am Anim Hosp Assoc* 1990 Jul/Aug; 26: 410-2.
10. Fingerroth JM, Smeak DD. Methylene blue infusion [Letter]. *J Am Anim Hosp Assoc* 1991; 27(3): 259.
11. Rumbelha WK, Oehme FW. Methylene blue can be used to treat methemoglobinemia in cats without inducing Heinz body hemolytic anemia. *Vet Hum Toxicol* 1992 Apr; 34(2): 120-2.
12. Davis LE. Nitrate intoxication. *J Am Vet Med Assoc* 1980 Jul 1; 177(1): 82-3.



Australian Government  
Department of Industry and Science

**Business**  
Cooperative Research  
Centres Programme